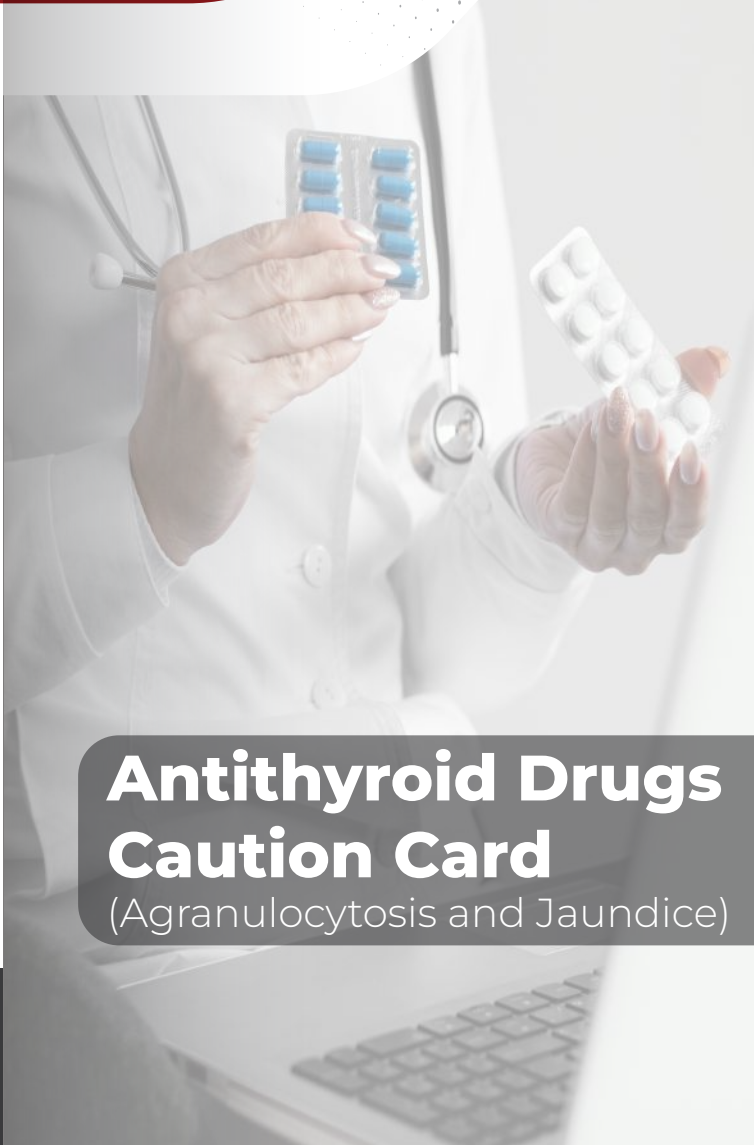


Shalamar Hospital is striving to provide our patients quality health care, at lowest possible costs. Our hospital is continually active in pioneering new treatments and therapies to improve the lives of people in our community.



Antithyroid Drugs Caution Card


(Agranulocytosis and Jaundice)

ENDOCRINE SURGERY CLINIC

Department of Surgery, Shalamar Hospital

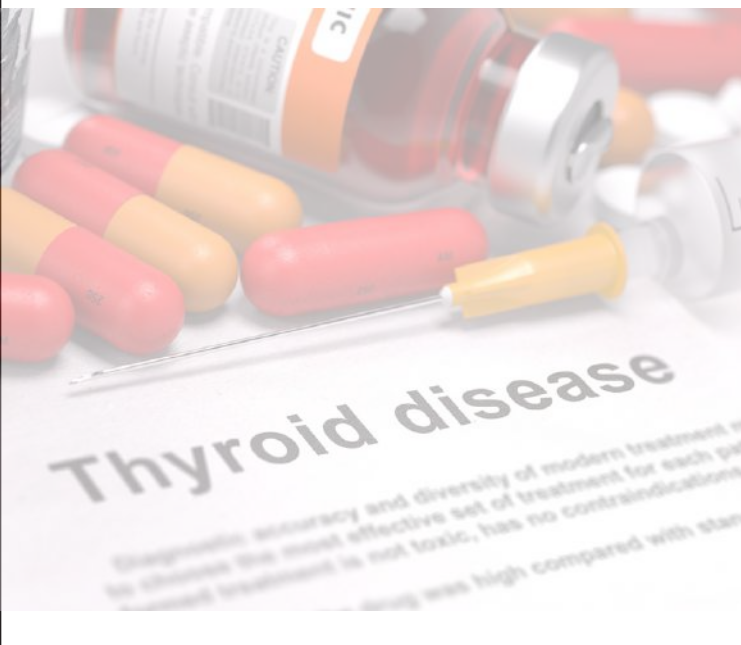 Shalimar Link Road, Lahore.

 Shalamar74

 +92 (42) 111-205-205 Ext: 325

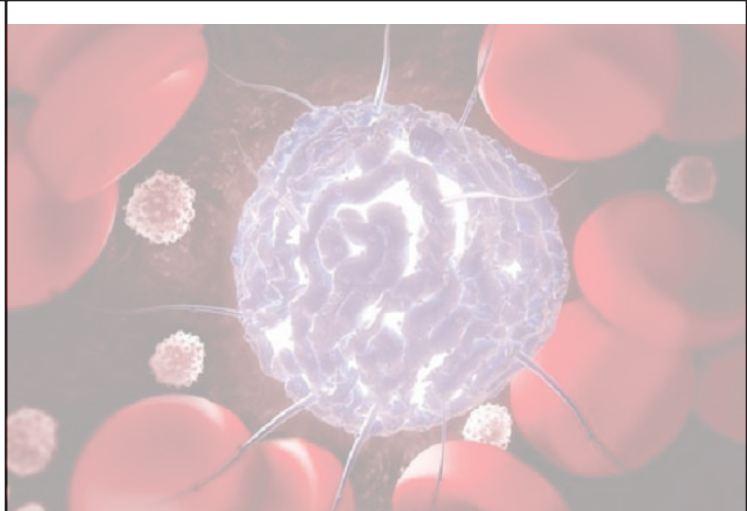
 www.shalamarhospital.org.pk

If Antithyroid drugs (ATD), such as Carbimazole or Propylthiouracil (PTU), have been prescribed to regulate your hyperactive thyroid, As with any medication, antithyroid drugs (ATD) can have side effects, some of which can be serious and potentially life-threatening. It is important to be aware of these risks, and this information card provides details about the most severe rare side effects and what steps to take if you experience them.



AGRANULOCYTOSIS

ATD can impact the production of white blood cells, which are responsible for fighting infections, leading to a severe condition called agranulocytosis. Though rare, it can affect a small number of people. If you experience symptoms like a sore throat, mouth ulcers, or fever, discontinue the medication immediately and seek medical attention from your doctor or A&E for a complete blood count urgently. Although these symptoms are common and may not be related to the ATD, it's crucial to get yourself checked.



JAUNDICE

PTU, a type of antithyroid drug, has been associated with serious liver injury in rare cases. In the event of yellowing of the skin or eyes, nausea, or loss of appetite, patients should contact their doctor immediately. For healthcare professionals, if a patient experiences symptoms such as sore throat, fever, or mouth ulcers, this could indicate agranulocytosis. Antithyroid medication should be discontinued immediately and a complete blood count should be urgently checked. Antithyroid medication should not be resumed until the blood count is normal.

